

Case report

Use of casting motion to mobilize stiffness to regain digital flexion following Dupuytren's fasciectomy

Robyn Midgley

Hand and Upper Limb Therapy, Occupational Therapy Department, Guy's & St Thomas NHS Foundation Trust, Guy's Hospital, London, UK

Correspondence: Robyn Midgley BSc (Hons) (Occupational Therapy) AHT (BAHT), Highly Specialist Occupational Therapist, Hand and Upper Limb Therapy, Occupational Therapy Department, Guy's & St Thomas NHS Foundation Trust, Ground Floor, Tower Wing, Guy's Hospital, London SE1 9RT, UK. Email: Robyn@handconsult.com

Abstract

Background. A priority in hand therapy following Dupuytren's fasciectomy is to regain and maintain extension of the proximal interphalangeal joint (PIPJ). Historically this has been achieved through the application of mechanical stress to the affected digit with splinting and exercise. However, loss of a normal pattern of digital flexion in both the operated and non-operated digits is a common complication.

Method. Four patients who underwent a Dupuytren's fasciectomy presented with persistent digital stiffness and a poor pattern of motion of the operated hand following traditional therapy. The casting motion to mobilize stiffness (CMMS) technique was therefore applied. The type of cast applied, duration of casting, duration of sessions and cast exercises are described.

Results. All patients regained digital flexion and an improved pattern of motion through the use of the CMMS technique without compromising PIPJ extension.

Conclusion. This small case series demonstrates the use of the CMMS technique to regain digital flexion and a normal pattern of motion when traditional treatment fails to achieve the desired outcomes following Dupuytren's fasciectomy. The use of the CMMS technique was beneficial in these patients and provides a means to regain digital flexion without the loss of PIPJ extension and is successful even when traditional therapy has failed.

Keywords: Dupuytren's fasciectomy, joint stiffness, rehabilitation, CMMS technique

Introduction

Dupuytren's disease

Dupuytren's disease is a fibroproliferative condition of the hand that is characterized by pitting and thickening of the palmar fascia that can be complicated by the development of a cord that extends into the affected fingers, resulting in a progressive digital flexion contracture of the metacarpophalangeal joint (MPJ) and interphalangeal joint (IPJ).¹

The precise aetiology of Dupuytren's disease is poorly understood.² Emerging bioscientific research has provided a better understanding of how surgery may improve the condition; however, there are no new treatments.³ Comparative clinical trials have made little contribution to surgical practice, resulting in a need to analyse factors that could lead to the success or failure of surgery in individual cases.³ The surgical management of

Dupuytren's disease is considered to be effective if there is an agreed satisfactory correction of joint contracture(s) and improved functional flexion of the digital joints. To a certain degree, a loss of extension following surgery is inevitable. However, loss of digital flexion is reported to occur in 40% of patients who have undergone surgery⁴ and can be more disabling than their original deformity.

There is limited evidence to suggest that postoperative splinting and therapy regimens are effective following Dupuytren's fasciectomy.^{5–7} Evidence is sparse, of poor quality and contradictory as studies report both positive and negative effects.⁷ Some evidence suggests that overly aggressive traditional therapeutic regimens could contribute to poorer results and to the recurrence of the disease.⁸ Overzealous splinting and exercise can increase flare-up and advance the disease process.⁵

Hand therapy aims to provide a postoperative regimen that maintains extension of the operated digit and encourages digital flexion while prioritizing wound

healing over joint motion in the early stages of treatment. Traditionally, this is achieved through the application of mechanical stress to the proximal interphalangeal joint (PIPJ) in extension through the use of splints and mobilization of the stiff joints. Current literature does not provide an alternative method of managing the post-operative complication of persistent digital stiffness in both the operated and non-operated digits.

A flexion contracture of the MPJ alone is usually correctable in most patients without developing postoperative complications, but a flexion contracture of the PIPJ that is greater than 30° can be more difficult to treat.⁹ This is largely due to the pretendinous cords producing contracture of the MPJ, while contracture of the PIPJ involves the spiral, central and lateral cords.¹⁰ Longstanding PIPJ contracture causes secondary joint changes, which have implications for the surgical and therapeutic management of the disease.⁹

Postoperative complications such as excessive inflammation, infection, haematoma, delayed wound healing, complex regional pain syndrome, pain, persistent PIPJ contracture, distal interphalangeal joint (DIPJ) hyperextension deformity and scar contracture may all contribute to prolonged digital stiffness and poor hand function.

This case series report describes the benefits of applying the casting motion to mobilize stiffness (CMMS) technique when traditional therapy has failed to adequately reduce postoperative joint stiffness following Dupuytren's fasciectomy without the application of mechanical stress and without the loss of PIPJ extension.

CMMS involves the use of a comfortable non-removable Plaster of Paris cast that selectively immobilizes proximal joints in an ideal position while constraining distal joints in order to direct the desired joint motion over a long period of time.¹¹ The advantage of this technique is that the cast prevents the application of excessive mechanical stress to the diseased tissue and allows for an appropriate prolonged stress that accommodates the physiological limits of the operated tissue to be applied through active motion only. A reduction in collagen cross-linking is therefore facilitated, which enables an elastic tissue response.¹¹ This approach supports the evidence of *in vitro* studies that demonstrate that stress may have an accelerated effect on the fibroproliferative process in Dupuytren's tissue.¹² Oedema is reduced by a combination of tissue compression by the hardened static cast and skin motion that is created by digital flexion, which provides physical stimulation of

superficial lymphatics. Scar healing occurs as the result of a prolonged low-load positive force that facilitates tissue elongation¹¹ and influences scar re-modelling.¹³ In addition, scar healing is enhanced through cast pressure and warmth, which reduces scar adherence and encourages a lubricated scar that is tolerant to friction.¹¹

The unique properties of Plaster of Paris enable the material to conform intimately to the scar tissue,¹⁴ thereby reducing the possibility of developing pressure areas and reducing the shear force of the cast on the skin,¹⁴ resulting in a tissue response that is superior to the tissue response with thermoplastic splints.¹¹

Methods

Four patients underwent a primary Dupuytren's fasciectomy by a consultant orthopaedic surgeon (Table 1). The open palm technique was used with standard wound closure, with the exception of the second patient who had a split skin graft over the ring finger MPJ and a flap over the proximal phalanx. He developed an infection post-operatively. The second and third patients both had delayed wound healing of nine and five weeks, respectively. All patients were provided with a Plaster of Paris cast in the operating theatre. A night-time extension splint was provided following the removal of the postoperative dressings and active and passive joint mobilization exercises were initiated one week after surgery.

All patients presented with postoperative complications of oedema, multiple joint stiffness, adherent scar tissue and a dominant intrinsic pattern of motion (Figure 1). None of the patients developed complex regional pain syndrome or had any pain. Initially, complications were managed using traditional therapy (Table 2), which did not achieve the desired outcomes; therefore, the CMMS technique was applied with patient consent.

Data collection

A standard goniometer was used to assess active range of motion (AROM) of the joints of the affected digits and was recorded before, during and after cast application by the same treating occupational therapist. In addition, the pattern of active digital flexion was observed.

Table 1 Patient profile, medical, surgical and therapeutic history

Patient	Age	Sex	History of Dupuytren's disease (years)	Risk factors	Operated digit (s)	Surgical status	Traditional therapy total duration (weeks)	No. of sessions	CMMS total duration (weeks)	No. of sessions
A	78	Male	5	None	Left RF	Primary	4	14	5	7
B	62	Male	8	Type II Diabetic Smoker Alcohol	Left RF	Primary	11	18	18	9
C	57	Male	10	Type I Diabetic	Right RF, LF	Primary	18	15	6	4
D	63	Female	5	None	Right RF, LF	Primary	5	13	15	8
Mean	65		7				9.5	15	11	7

RF, ring finger; LF, little finger

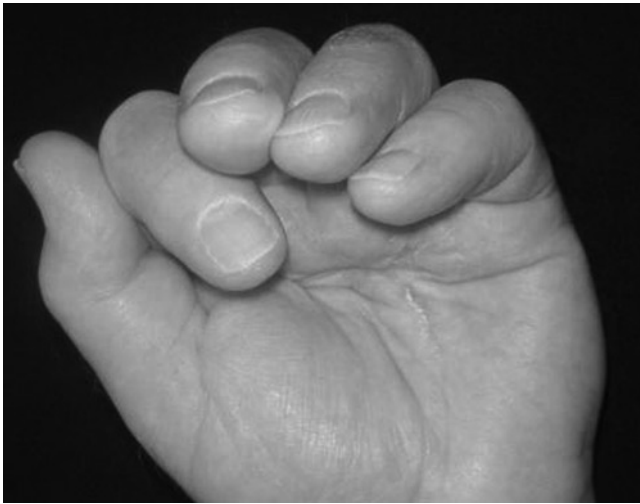

Figure 1 Dominant intrinsic plus pattern of motion and digital flexion following 11 weeks of traditional therapy

Objective means of quantifying the changes in pattern of movement or changes in soft tissue do not currently exist. Direct palpation is the only means of demonstrating the quality of soft tissue change.¹¹ Digital photography and video recording were used to assure observations were accurately recorded.

Cast design

The presence of Dupuytren's disease restricts full MPJ extension for prolonged periods of time, resulting in the development of adaptive intrinsic muscle tightness. When

Table 2 Summary of postoperative complications and traditional hand therapy provided

Postoperative complications	Traditional hand therapy provided
Oedema	Oedema management (Coban, ice, contrast baths)
Delayed wound healing	Rest and gentle active mobilization exercises
Infection	Wound management, rest and gentle active exercise regimen
Multiple joint stiffness	Active and passive mobilization exercises, joint blocking exercises and light therapeutically exercises
Pain	Pain management through the use of contrast bathing, ice or heat application
Adherent scar tissue	Scar management (silicone, massage and vibration)
Intrinsic muscle tightness	Tendon glide exercises and intrinsic muscle stretches
Dominant intrinsic pattern of flexion	Education with regards to normal digital flexion patterns
Increased wrist flexor activity during digital flexion	Immobilize the wrist using a futura splint during digital flexion exercises
Poor functional use of the hand	Encourage early use of the affected hand

CMMS, casting motion to mobilize stiffness

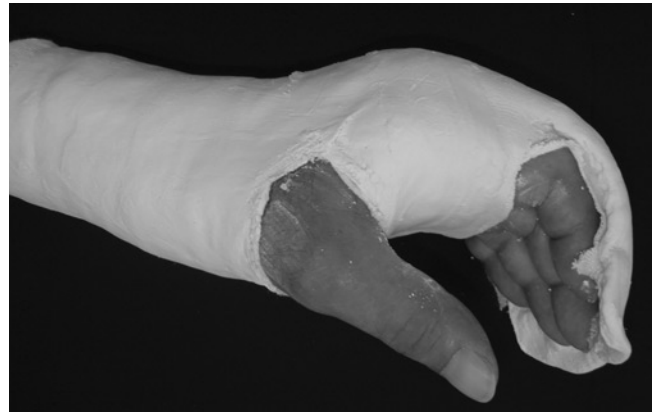


Figure 2 Cast design to block metacarpophalangeal joints in extension while allowing active interphalangeal joint flexion to elongate the intrinsic muscles

the MPJ is released surgically and extension is regained, the patient continues to have difficulty initiating digital flexion with flexor digitorum profundus (FDP) due to intrinsic muscle tightness. This leads to an abnormal pattern of movement with the MPJs initiating flexion. Therefore, an appropriate cast design that blocks the MPJs in extension yet allows active PIPJ flexion to elongate the intrinsic muscles is required (Figure 2). The same cast design was applied to each patient by the treating occupational therapist and was specific to the altered dominant intrinsic plus pattern of motion. Each cast was applied to the forearm and hand, positioning the wrist in 20° of extension and the MPJs blocked in extension. As FDP glide was poor in all patients, a dorsal hood was added to position the DIPJs in relatively greater flexion than the PIPJs. This ensured that FDP initiated movement, thereby allowing active IPJ flexion to elongate the intrinsic muscles and restore a normal pattern of motion whereby digital motion is initiated with DIPJ flexion.

The use of a dorsal hood to position the IPJs in greater flexion than the MPJs has been validated by Arbuckle and McGrouther,¹⁵ who showed that the normal pattern of digital flexion is initiated with IPJ flexion prior to any significant MPJ flexion. Flexion contractures of the PIPJs are avoided if care is taken to ensure that DIPJ flexion exceeds PIPJ flexion and if joint motion is facilitated in both directions at the same time with movement occurring only at the site of greatest stiffness as all proximal joints are restrained.¹¹ The PIPJ and DIPJ should not be held at absolute end range of motion, but rather be positioned within the cast to optimize active motion. This position is particularly useful when both PIPJ flexion and extension motion is poor.¹¹

The casts were not removable during the early stages of treatment and were weaned slowly when removed. A bivalve (removable) cast was provided during the weaning phase of treatment. If a patient has significant joint stiffness and requires a cast for extended periods of time, as with patients C and D, then a bivalve cast can be applied earlier. However, the patient should only remove the cast for hygiene purposes and should not use the hand to perform functional activities as this would interfere with long-term re-patterning of the cortex.

Cast exercises

In order for the motor cortex to learn the new normal pattern of motion and for long-term re-patterning of the cortex to be achieved and maintained, repeated digital motion in the desired pattern within the cast is needed over a long period of time.^{16,17}

The cast exercises included mobilizing all the fingers actively and continuously into a hook fist within the cast with regular rest periods. The repeated cyclical motion of the fingers within the cast assists to reduce joint stiffness and restore a normal pattern of motion in both the operated and non-operated digits. The cast was reviewed and changed by the occupational therapist every 2–3 weeks. Prior to the application of a new cast, AROM was assessed using a standard goniometer. Video and photography was used with consent to record and compare changes in tissue quality and pattern of motion. This provided the patients with the motivation to continue with the technique as they could use the media to review their progress and goals.

The duration of time spent in a cast depends on two factors: the length of time it takes for the new 'normal' movement pattern to be re-patterned within the motor cortex and the amount of time it takes for the tight intrinsic muscles to reach their maximum length.¹¹ The patient had to demonstrate the new desired pattern of motion within the cast for approximately two weeks and spontaneously demonstrate a normal tenodesis pattern out of the cast prior to the cast being removed permanently. Slow weaning of the patient out of a cast is imperative as this prevents the recurrence of dominant MPJ flexion pattern and joint stiffness. On average, patients require a weaning period within a bivalve cast of approximately two weeks.

Results

The patients in this case report received an average of 9.5 weeks of traditional therapy and attended 15 treatment sessions following a primary Dupuytren's fasciectomy before the CMMS technique was applied. An average of 11 weeks of CMMS following traditional treatment and seven treatment sessions were required to restore a normal pattern of digital motion (Table 1).

Each patient regained digital flexion and a normal pattern of motion through the use of the CMMS technique without compromising improvements made in PIPJ extension of the operated digits (Figure 3). Figures 1 and 4 provide an example of limited digital flexion and poor scar condition after 11 weeks of traditional therapy in patient B. This can be compared with the improvements made in digital flexion and the scar condition in Figures 5 and 6 after seven weeks of CMMS. Figures 7 and 8 demonstrate improvements made in PIPJ and DIPJ flexion before and after the application of the CMMS technique.

The scar condition improved in each patient following the application of a cast. It is expected that scar improvement will occur with time, but it appears as if the scar maturation process is facilitated by a Plaster of Paris cast due to the constant pressure and warmth that the cast provided (Figure 6). Silicone was not applied to the scars during casting.

These results suggest a positive response to the application of the CMMS technique in this group of patients.

Discussion

The restoration of a patient's full range of motion and function are the primary goals of hand therapy. The

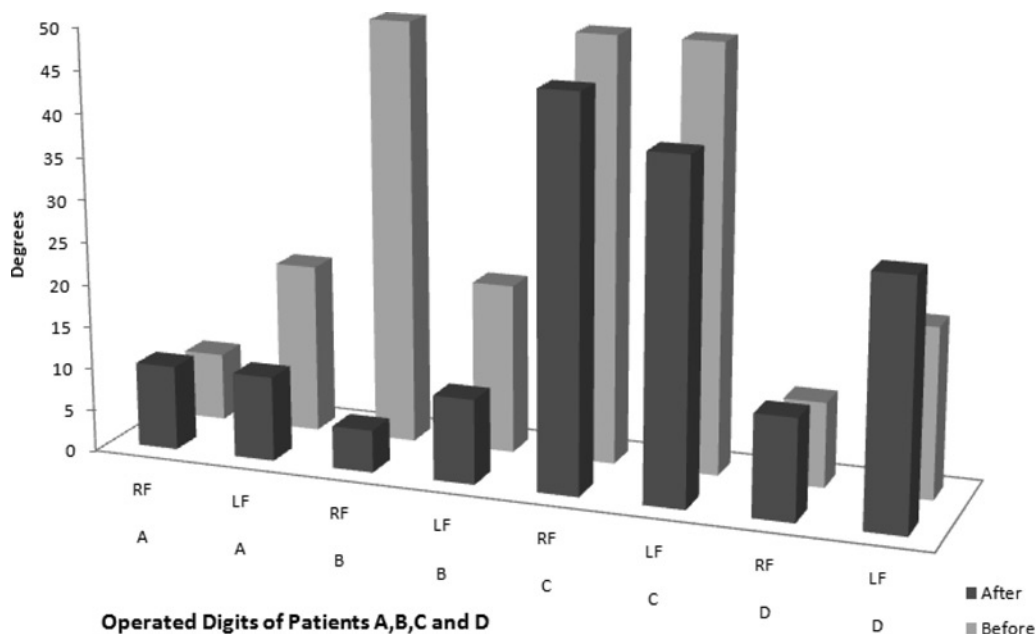


Figure 3 Active proximal interphalangeal joint (PIPJ) extension before and after the application of the casting motion to mobilize stiffness (CMMS) technique

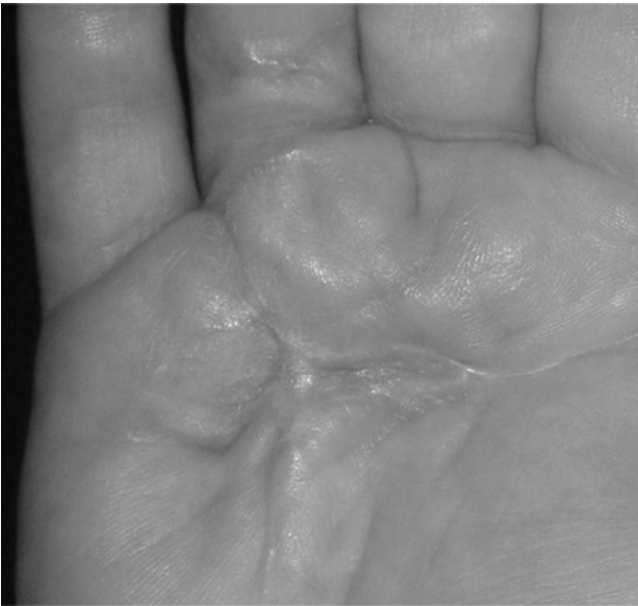

Figure 4 Scar condition following 11 weeks of traditional therapy

nature of Dupuytren's disease is such that prolonged immobilization of joint structures results in adaptive shortening in the periarticular tissues such as the joint capsule, ligaments, fascia and the muscle-tendon unit.⁹ The development of postoperative complications in addition to the pre-existing changes in the periarticular structures provides a significant challenge for the hand therapist.

The application of stress to the involved tissues can contribute to permanent changes in the periarticular structures and surrounding musculature, thereby

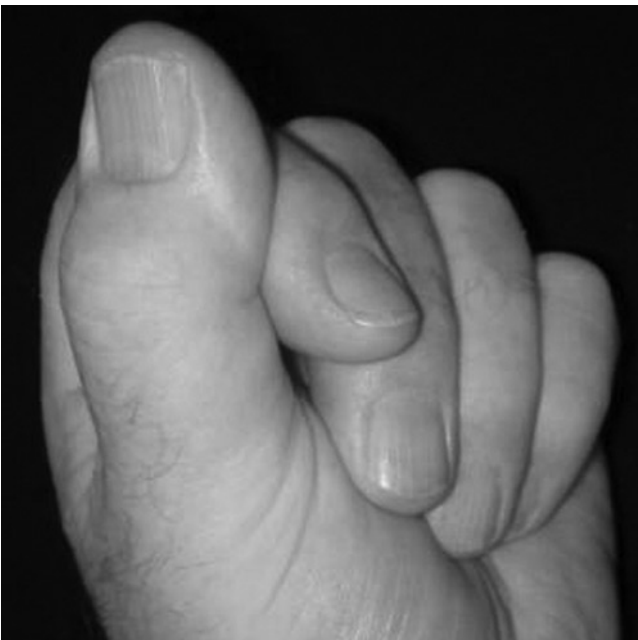

Figure 5 Digital flexion result following seven weeks of casting motion to mobilize stiffness (CMMS)

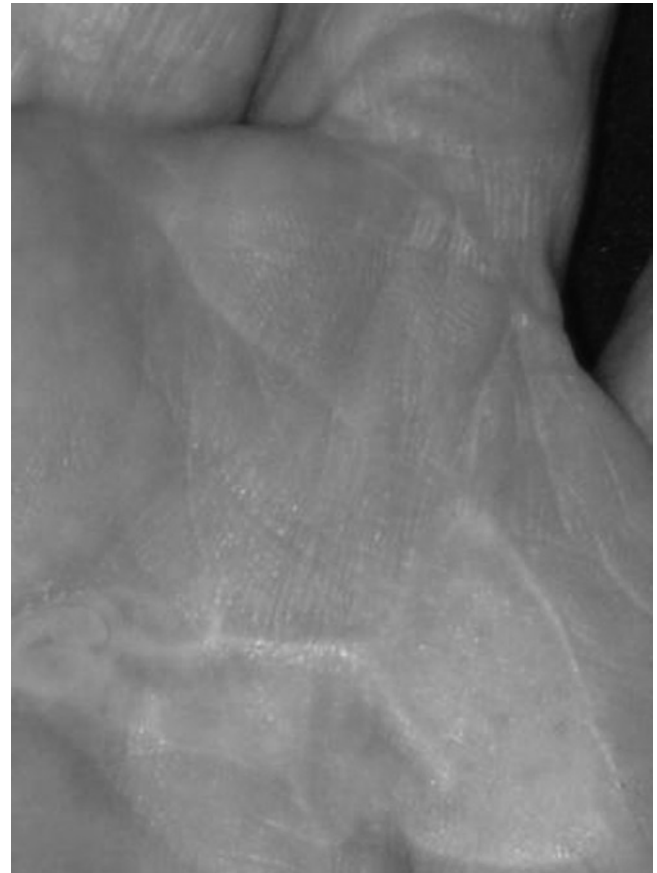


Figure 6 Scar condition following seven weeks of casting motion to mobilize stiffness (CMMS)

improving joint stiffness and function.¹⁸ It is up to the hand therapist to determine the intensity and duration of the stress that is applied. Optimal plastic deformation occurs with the application of low-load prolonged stress over a long period of time. The application of a specially designed cast using the CMMS technique is one way in which the desired stress can be applied.

The advantage of the CMMS technique is that patients do not have to endure extensive home exercise programmes and require fewer hand therapy sessions than those receiving traditional hand therapy (Table 1). However, specialist skill is required for precise application and safe removal of a Plaster of Paris cast. It is recommended that therapists are formally trained to use the technique, which will limit its application. Patients may find it inconvenient to wear a cast for a long period of time and may not favour its heavier weight compared with thermoplastic splints. Patients in this study reported that the cast was 'comfortable, helped them to regain movement in both directions and could feel the enhanced healing process through the pressure of the cast'. Patients also found that the constraint of proximal joints helped them to 're-learn how to move their fingers'.

The literature reports a large variation in practice and criteria for using splinting as part of the postoperative management plan following Dupuytren's fasciectomy.⁷ Subsequently, researchers are in the process of implementing a multicentre pragmatic randomized controlled

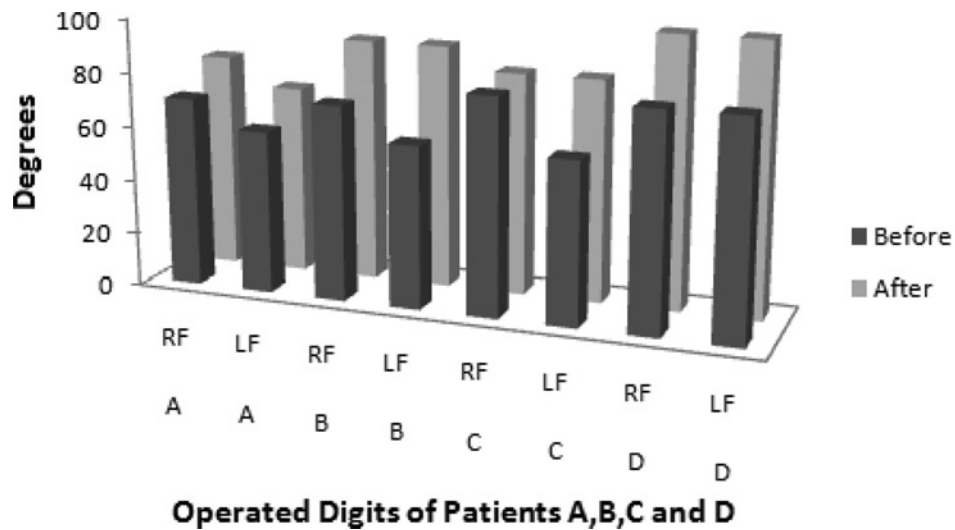


Figure 7 Active proximal interphalangeal joint (PIP) flexion before and after the application of the casting motion to mobilize stiffness (CMMS) technique

trial that aims to evaluate the effectiveness of postoperative static night splinting on hand function, range of motion, patient satisfaction and recurrence at one year after fasciectomy or dermofasciectomy. It is expected that this trial will provide the evidence that is needed to evaluate the clinical effectiveness of postoperative night splinting following Dupuytren's fasciectomy or dermofasciectomy.¹⁹

The results of this case series shows a positive response to the use of the CMMS technique following Dupuytren's fasciectomy when traditional therapy does not correct the postoperative complication of persistent digital stiffness in the operated and non-operated digits. However, this is a small study and does not provide conclusive scientific evidence to support the use of the CMMS technique with all patients following Dupuytren's fasciectomy. It does, however, raise the question of the role splinting has in the

postoperative management of Dupuytren's disease. Further research is needed to establish what the outcomes would be if CMMS was used as opposed to splinting to prevent the onset of persistent digital stiffness and other complications such as adherent scar tissue. It is recommended that a randomized controlled trial be implemented, whereby the outcomes of patients who are treated with splinting and traditional therapy can be compared with those who are treated with the CMMS technique alone.

Conclusion

Postoperative complications following Dupuytren's fasciectomy can compromise both the appearance and function of the hand.

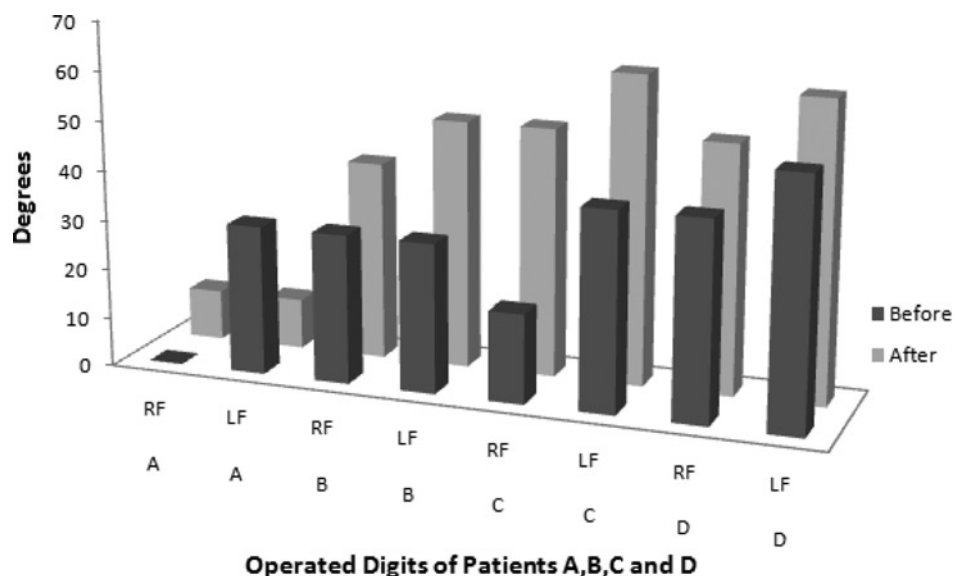


Figure 8 Active distal interphalangeal joint (DIP) flexion before and after application of the casting motion to mobilize stiffness (CMMS) technique

This paper presents the use of CMMS to resolve post-operative complications following Dupuytren's fasciectomy in order to regain digital flexion without the need to apply a mechanical force in the form of splinting and without the risk of losing PIPJ extension. It is suggested that the CMMS technique be applied as soon as post-operative complications such as persistent oedema, multiple joint stiffness and an abnormal pattern of motion become evident. The application of a cast promotes the release of joint tightness and scar tissue adherence and reduces oedema so that joint motion can be restored. Delayed wound healing should not prevent the application of a cast as the cast does not cause maceration, but caution is warranted in the presence of a wound infection.

Acknowledgements: Sincere thanks are extended to Judy C Colditz, OT/L, CHT, FAOTA, for the development of the CMMS technique, for her years of mentoring and for her continued support of this paper.

Competing interest: None declared.

Accepted: 23 February 2010

References

- Swartz WM, Lalonde DH. Dupuytren's Disease. *Plastic Reconstr Surg* 2008;121:1–10
- McFarlane R, Botz J, Cheung H. Epidemiology of surgical patients. In: McFarlane D, Flint M, eds. *Dupuytren's Disease: Biology and Treatment*. Edinburgh: Churchill Livingstone, 1990
- McGrouther DA. Dupuytren's contracture. In: Green DP, ed. *Operative Hand Surgery*. 5th edn. Philadelphia: Churchill Livingstone, 2005
- Schneider IH, Hankin FM, Eisenberg T. Surgery of Dupuytren's disease: a review of the open palm method. *J Hand Surg* 1986;11A:23–7
- Evans RB, Dell PC, Fiolkowski P. A clinical report of the effect of mechanical stress on functional results after fasciectomy for Dupuytren's contracture. *J Hand Ther* 2002;15:331–41
- Abbott K, Denney J, Burke FD, McGrouther DA. A review of attitudes to splintage in Dupuytren's contracture. *J Hand Surg* 1987;12B:326–8
- Larson D, Jerosch-Herold C. Clinical effectiveness of post-operative splinting after surgical release of Dupuytren's contracture: a systematic review. *BMC Musculoskel Disord* 2008;9:104
- Glasse N. A study of the effect of night extension splinting on post-fasciectomy Dupuytren's patients. *Br J Hand Ther* 2001;6:89–94
- Azad SM, Cherian A, Raine C, Dixon J, Irvine B, Erdmann MWH. Dupuytren's disease: an overview of aetiology, pathology and treatment. *Br J Hand Ther* 2001;6:73–8
- Benson LS, Williams CS, Kahle M. Dupuytren's contracture. *J Am Acad Orthop Surgeons* 1998;6:24–35
- Colditz J. Plaster of Paris: the forgotten hand splinting material. *J Hand Ther* 2002;15:144–57
- Citron N, Hernden A. Skin tension in the aetiology of Dupuytren's disease; a prospective trial. *J Hand Surg – Br Eur Vol* 2003;28:66, 528–30
- Fess EE, McCollum M. The influence of splinting on healing tissues. *J Hand Ther* 1998;11:157–61
- Bell JA. Plaster casting in the remodelling of soft tissue. In: Fess EE, Philips CA, eds. *Hand Splinting: Principles and Methods*. 2nd edn. St Louis: CV Mosby, 1987
- Arbuckle JD, McGrouther DA. Measurement of the arc of digital flexion and joint movement ranges. *J Hand Surg* 1995;20B:836–40
- Kaas JH. Plasticity of sensory and motor maps in adult mammals. *Ann Rev Neurosci* 1991;14:137–67
- Merzenich M, Kaas J, Wall J, Nelson R, Sur M, Felleman D. Progression of change following median nerve section in the cortical representation of the hand in areas 3b and 1 in adult and owl and squirrel monkeys. *Neuroscience* 1983;10:639–65
- Cyr LM, Ross RG. How controlled stress affects healing tissues. *J Hand Ther* 1998;11:125–30
- Jerosch-Herold C, Shepstone L, Chojnowski AJ, Larson D. Splinting after contracture release for Dupuytren's contracture (SCoRD): protocol of a pragmatic, multi-centre, randomized controlled trial. *BMC Musculoskel Disord* 2008;62:1471–2474